

Benign Pneumoperitoneum After Diagnostic Colonoscopy in a Patient Followed Up for Crohn's Disease

Ferdaouss Lamarti¹, Mohamed Borahma¹, Nawal Lagdali¹, Imane Benelbarhdadi¹,
Fatima-Zohra Ajana¹, Omar El Aoufir², Laila Laamrani²

¹Department of Gastroenterology C, Mohammed V University, Ibn Sina Hospital, Rabat, Morocco

²Department of Radiology, Mohammed V University, Ibn Sina Hospital, Rabat, Morocco

Email address:

F.lamarti@hotmail.fr (F. Lamarti)

To cite this article:

Ferdaouss Lamarti, Mohamed Borahma, Nawal Lagdali, Imane Benelbarhdadi, Fatima-Zohra Ajana, Omar El Aoufir, Laila Laamrani. Benign Pneumoperitoneum After Diagnostic Colonoscopy in a Patient Followed Up for Crohn's Disease. *International Journal of Medical Case Reports*. Vol. 1, No. 2, 2022, pp. 13-16. doi: 10.11648/j.ijmcr.20220102.12

Received: May 13, 2022; Accepted: May 30, 2022; Published: June 16, 2022

Abstract: Colonoscopy is a safe procedure with a low incidence of complications. Perforation is the complication most feared by the gastroenterologist. The management of benign pneumoperitoneum after colonoscopy is controversial. It is defined as asymptomatic free intra-abdominal air or as pneumoperitoneum without peritonitis. It may not require treatment. We present this case because of its rarity and controversial treatment options. This is a 46-year-old patient followed for luminal colic Crohn's disease under Adalimumab admitted to a day hospital for a colonoscopy in the context of monitoring. The latter had objectified a severe left flare and was not totaled because of the risk it ran for the patient. On waking, the patient presented with diffuse abdominal pain that resolved after gas evacuation. An abdominal CT scan was nevertheless performed, showing right prehepatic and pericolic pneumoperitoneum without peritoneal effusion. It was decided in consultation with the surgeons to opt for digestive rest and to keep the patient under strict surveillance without starting any treatment given that the patient was asymptomatic, afebrile, hemodynamically stable and the abdominal examination was strictly normal. The patient showed no clinical worsening during the follow-up and the pneumoperitoneum clearly regressed on the follow-up CT scan. It is necessary in case of pneumoperitoneum to confront the imaging to the clinic by remaining above all a clinician in order to be able to reserve conservative treatment for well-chosen patients.

Keywords: Colonoscopy, Pneumoperitoneum, Crohn's Disease

1. Introduction

Colonoscopy is a safe procedure with a low incidence of complications [1].

Perforation is the complication most feared by the gastroenterologist, because it is potentially fatal and can lead to dilapidating surgery with the placement of a stoma. This risk of perforation, even during a diagnostic colonoscopy, is not zero. It is significantly more frequent for symptomatic patients than during a screening examination [2].

Its incidence is then 0.3/1,000 colonoscopies vs. 1.3/1,000 in the presence of symptoms [3].

It can present either as an obvious clinically apparent perforation and then require a laparotomy, or as a microperforation which will generally be treated by antibiotic therapy administered intravenously and bowel rest,

sometimes associated with endoscopic treatment consisting of the placement of clips [4-7].

On the other hand, the management of benign pneumoperitoneum after colonoscopy is controversial. It is defined as asymptomatic free intra-abdominal air or as pneumoperitoneum without peritonitis [1, 8, 9]. It would be linked either to a clinically undetectable microperforation or to a transmural passage of air insufflated by the endoscopist, especially if the insufflation is excessive. It may not require treatment [1].

We present this case because of its rarity and controversial treatment options.

2. Case Presentation

This is a 46-year-old patient followed for luminal colic Crohn's disease since 2010 on Adalimumab since 2018 at the

rate of one injection per week who was admitted to a day hospital for a colonoscopy as part of a monitoring.

The latter had objectified a severe attack on the left with erythematous mucosa seat of large superficial ulcerations as well as a narrowing of 10 cm from 20 to 30 cm of the anal margin, crossed under visual control by friction. Beyond 60 cm from the anal margin, the mucosa was normal but the colonoscopy was not totaled because of the risk it incurred for the patient given the left thrust.

On waking, the patient presented with diffuse abdominal pain with a tender abdomen as a whole. The latter completely faded 10 min after waking up after gas evacuation and the abdomen was supple on clinical examination.

In a systematic spirit, an abdominal CT scan was still performed showing a regular circumferential partial thickening of the rectum extended to the entire colonic frame enhanced after injection of contrast product with submucosal edema measuring 9mm maximum thickness with fat infiltration adjacent and a few locoregional lymph nodes, as well as right prehepatic and pericolic pneumoperitoneum without peritoneal effusion.

The chest x-ray centered on the domes also revealed a right gas crescent.

Biological assessment showed hyperleukocytosis at 14900 at the expense of PNN at 13250.

It was decided in consultation with the surgeons to opt for digestive rest and to keep the patient under strict surveillance without the initiation of any treatment given that the patient was asymptomatic, afebrile, hemodynamically stable and abdominal examination was strictly normal. The patient showed no worsening after 48 hours. There was normalization of the white blood cells on the control NFS. They were at 6380 and the PNNs were at 4170.

The gaseous crescent disappeared on the control radiograph and there was also a clear regression of the pneumoperitoneum on the control CT scan.

It was therefore decided to consider this pneumoperitoneum as benign not requiring surgical intervention and to discharge the patient by gradually resuming food while continuing to monitor him by teleconsultation.

As for his Crohn's disease, the patient was offered a therapeutic escalation, thus opting for Ustekinumab.

On D8, the patient was still perfectly asymptomatic, so we preferred to rely on the clinic and not repeat a CT scan to protect the patient from a 3rd irradiation.

3. Discussion

Colonoscopy is a powerful procedure used routinely by gastroenterologists [3]. Today, it remains the first-line examination for the diagnosis and treatment of colorectal pathologies with a low incidence of complications [1, 10].

Colonic perforation is a rare complication of colonoscopy but it can lead to serious complications with high morbidity and mortality rates [11, 12]. The frequency of perforations after colonoscopy is estimated at 0.02% for diagnostic colonoscopy and 0.09% for therapeutic colonoscopy,

particularly after polypectomy [13].

Pneumoperitoneum frequently indicates perforation of a hollow organ and requires urgent surgical management in 85 to 95% of cases [9]. 5–15% of cases of pneumoperitoneum do not reflect perforation and result from another cause not requiring emergency surgery [9].

This is the case of benign pneumoperitoneum which is defined as asymptomatic free intra-abdominal air or pneumoperitoneum without peritonitis. It appears as a characteristic radiolucency seen below the diaphragm on chest X-ray [1, 9]. It has been well described in various clinical scenarios in addition to colonoscopy, for example, after percutaneous endoscopic gastrostomy, laparotomy or pneumatosis intestinalis [1]. It has been speculated that it would occur more frequently after polypectomy or difficult colonoscopies, or simply following transmural passage of insufflated air using excessive insufflations [1, 9, 10].

Rare studies have prospectively investigated benign pneumoperitoneum after colonoscopy [1, 13]. The vast majority of studies examining complications of colonoscopy were retrospective [14, 4]. Therefore, all cases of pneumoperitoneum were discovered in symptomatic patients who had radiographs due to abdominal pain [1].

Pearl and al. [1] and Ecker and al. [13] conducted a prospective study and were unable to detect benign pneumoperitoneum after colonoscopy, but the study was conducted on a limited sample of 100 patients. Our knowledge of benign pneumoperitoneum is therefore limited to a few case reports [15, 16]. According to these reports, it is rare after diagnostic and therapeutic colonoscopy, with an incidence of 0% to 3% [1].

Ustek and al [17] reported the case of a patient who had a diagnostic colonoscopy for pain in the right hypochondrium and constipation. Despite the fact that the latter took place without incident, the patient had abdominal pain after the procedure which gradually increased in intensity significantly and which was related to pneumoperitoneum objectified both on the abdomen without preparation and on the scanner. The patient had a laparotomy but no perforation was detected. It was therefore decided that the reason for the pneumoperitoneum was transmural air passage or microperforation, not perforation. Oral feeding was resumed on the 3rd postoperative day and on the 7th postoperative day, there was a complete disappearance of the pneumoperitoneum in the abdomen without preparation.

Seitz et al. [18] also reported the case of benign pneumoperitoneum after diagnostic colonoscopy in an 11-year-old child followed up for Crohn's disease in whom surgery ruled out gastrointestinal perforation and peritonitis. The patient evolved well after intravenous antibiotic therapy and was able to leave the hospital on the 6th postoperative day.

Seung-Jae Myung [19] and al also reported the case of a 71-year-old patient followed for left UC for 5 years who had developed pneumoperitoneum and retropneumoperitoneum after rectosigmoidoscopy discovered following mild abdominal pain that appeared 3 hours after the gesture. No perforation site was identified on his CT scan. The patient

received only intravenous methylprednisolone for his flare. The pneumoperitoneum and retroperitoneum completely disappeared on the follow-up CT scan performed 2 weeks later.

Some believe that all patients with pneumoperitoneum after colonoscopy should undergo immediate surgery [20, 21] because early laparotomy is thought to be associated with less morbidity and mortality [22]. However, not all cases of pneumoperitoneum should be considered as perforation, especially if abdominal pain is minimal or non-existent and if peritoneal signs, namely fever and hyperleukocytosis, are absent.

In these cases, non-surgical causes of pneumoperitoneum or microperforation should be considered and these cases should be treated with intravenous antibiotics and bowel rest [1, 9, 10, 14, 23].

Transmural passage of air may require no treatment [1]. But conservative treatment should be reserved for carefully selected patients only [23].

In our case, this option was considered after consultation with the surgeons. Our patient was clinically asymptomatic, the clinical examination was normal with, in particular, a soft abdomen on palpation. The transient elevation of white blood cells could be explained by the gesture itself.

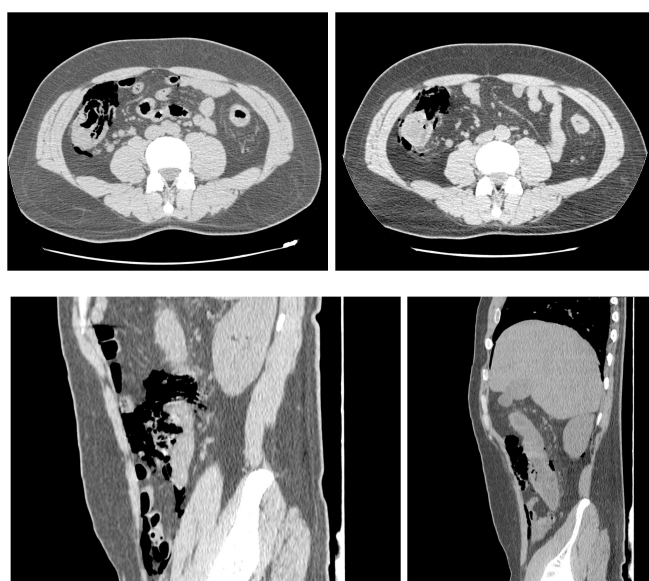


Figure 1. Decrease in pneumoperitoneum between the 1st scan of right vs left (D+2).

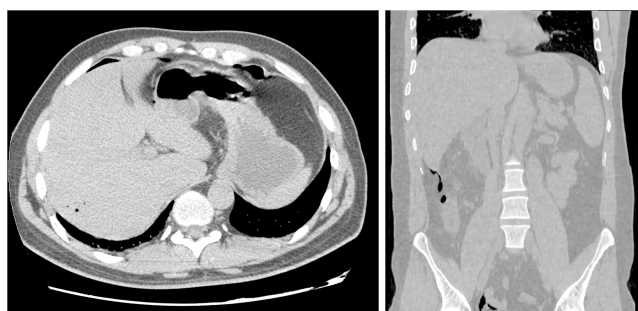

Figure 2. Disappearance of the subdiaphragmatic pneumoperitoneum between the 1st scan of the right vs left (D+2).

4. Conclusion

We raise the hypothesis that the benign pneumoperitoneum objectified after a colonoscopy would be an underestimated and unrecognized complication due to the absence of systematic abdominal CT scans after the procedure. This complication would be relatively more frequent in patients followed for IBD for a long time due to the fragility of the colonic and intestinal mucosa. Strict monitoring in these patients would therefore be wise.

The optimal treatment, whether conservative or operative, is still uncertain [23]. Until a large study defines the incidence and treatment options, all cases of pneumoperitoneum after colonoscopy should be treated with caution.

It is necessary to confront the imaging to the clinic by remaining above all a clinician in order to be able to reserve conservative treatment for well-chosen patients.

References

- [1] J. P. Pearl, M. P. McNally, E. A. Elster, and J. W. DeNobile, "Benign pneumoperitoneum after colonoscopy: a prospective pilot study," *Military Medicine*, vol. 171, no. 7, pp. 648–649, 2006.
- [2] Reumkens A, Rondagh EJA, Bakker CM, Winkens B, Masclee AAM, Sanduleanu S. Post- Colonoscopy Complications: A Systematic Review, Time Trends, and Meta-Analysis of Population-Based Studies. *Am J Gastroenterol*. 2016; 111 (8): 1092-101.
- [3] POST'U 2019. Gestion des complications endoscopiques de la coloscopie. Association française de formation médicale continue en hépato-gastro-entérologie.
- [4] Cobb WS, Heniford BT, Sigmon LB, et al: Colonoscopic perforations: incidence, management, and outcomes. *Am Surg* 2004; 70: 750–7.
- [5] Viiala CH, Zimmerman M, Cullen DJ, Hoffman NE: Complication rates of colonoscopy in an Australian teaching hospital environment. *Intern Med* 2003; 33: 355–9.
- [6] Damore LJ II, Rantis PC, Vernava AM III, Longo WE: Colonoscopic perforations: etiology, diagnosis, and management. *Dis Colon Rectum* 1996; 39: 1308–14.
- [7] Ker TS, Wasserberg N, Beart RW Jr: Colonoscopic perforation and bleeding of the colon can be treated safely without surgery. *Am Surg* 2004; 70: 922–4.
- [8] Y. T. Hui, W. M. Lam, T. W. Lam, W. C. Cheung, S. F. Sze, and C. T. Wong, "Benign pneumoperitoneum developed after endoscopic biliary metallic stent placement with the rendezvous procedure," *Gastrointestinal Endoscopy*, vol. 67, no. 1, pp. 179–180, 2008.
- [9] R. A. Mularski, J. M. Sippel, and M. L. Osborne, "Pneumoperitoneum: a review of nonsurgical causes," *Critical Care Medicine*, vol. 28, no. 7, pp. 2638–2644, 2000.
- [10] L. J. Damore II, P. C. Rantis, A. M. Vernava III, and W. E. Longo, "Colonoscopic perforations: etiology, diagnosis, and management," *Diseases of the Colon and Rectum*, vol. 39, no. 11, pp. 1308–1314, 1996.

- [11] G. Carpio, E. Albu, M. A. Gumbs, and P. H. Gerst, "Management of colonic perforation after colonoscopy: report of three cases," *Diseases of the Colon and Rectum*, vol. 32, no. 7, pp. 624–626, 1989.
- [12] D. Jentschura, M. Raute, J. Winter, T. Henkel, M. Kraus, and B. C. Manegold, "Complications in endoscopy of the lower gastrointestinal tract—therapy and prognosis," *Surgical Endoscopy*, vol. 8, no. 6, pp. 672–676, 1994.
- [13] M. D. Ecker, M. Goldstein, B. Hoexter, R. A. Hyman, J. B. Naidich, and H. L. Stein, "Benign pneumoperitoneum after fiberoptic colonoscopy. A prospective study of 100 patients," *Gastroenterology*, vol. 73, no. 2, pp. 226–230, 1977.
- [14] H. Kavin, F. Sinicrope, and A. H. Esker, "Management of perforation of the colon at colonoscopy," *American Journal of Gastroenterology*, vol. 87, no. 2, pp. 161–167, 1992.
- [15] C. U. Carlsen and K. H. Andreassen, "Benign pneumoperitoneum and scrotal emphysema after colonoscopy," *Ugeskrift for Laeger*, vol. 154, no. 25, pp. 1785–1786, 1992.
- [16] K. J. Goerg and C. Duber, "Retroperitoneal, mediastinal and subcutaneous emphysema with pneumothorax after colonoscopy," *Deutsche Medizinische Wochenschrift*, vol. 121, no. 21, pp. 693–696, 1996.
- [17] Sevim Ustek, Mertay Boran, and Kemal Kismet. Benign Pneumoperitoneum after Colonoscopy. Case Reports in Medicine. Volume 2010, Article ID 631036, 3 pages.
- [18] Sigurd T. Seitz, Aline Ruckel, Gregor Siebenlist, Manuel Besendorfer, Vera S. Schellerer. Case report: Tension pneumoperitoneum after diagnostic colonoscopy in an 11 y/o boy with Crohns disease. *International journal of surgery case reports* 75 (2020) 413-417.
- [19] Seung-Jae Myung, Suk-Kyun Yang, Jin-Ho Kim. Pneumoperitoneum in a Patient with Ulcerative Colitis After Sigmoidoscopy: Is This Always an Indication for Surgery? *Inflamm Bowel Dis* Volume 17, Number 6, June 2011.
- [20] S. Brynitz, H. Kjaergard, and J. Struckmann, "Perforations from colonoscopy during diagnosis and treatment of polyps," *Annales Chirurgiae et Gynaecologiae*, vol. 75, no. 3, pp. 142–145, 1986.
- [21] R. L. Nelson, H. Abcarian, and M. L. Prasad, "Iatrogenic perforation of the colon and rectum," *Diseases of the Colon and Rectum*, vol. 25, no. 4, pp. 305–308, 1982.
- [22] A. Ghazi and M. Grossmann, "Complications of colonoscopy and polypectomy," *Surgical Clinics of North America*, vol. 62, no. 5, pp. 889–896, 1982.
- [23] T. H. Luning, M. E. Keemers-Gels, W. B. Barendregt, A. C. T. L. Tan, and C. Rosman, "Colonoscopic perforations: a review of 30,366 patients," *Surgical Endoscopy and Other Interventional Techniques*, vol. 21, no. 6, pp. 994–997, 2007.