

Pulmonary Metastasis of Ewing's Sarcoma in Pediatric Age: Literature Review and Case Report

Caridad Verdecia Canizares^{1,5}, Luis Alexis Graveran Sanchez^{2,5}, Niurka Diaz Zayas^{3,5},
Damian Pineda Fernandez^{4,5}

¹Oncology Department, University Pediatric Hospital, William Soler Ledea, Havana, Cuba

²Surgical Department, University Pediatric Hospital, William Soler Ledea, Havana, Cuba

³Radiology Department, University Pediatric Hospital, William Soler Ledea, Havana, Cuba

⁴Anatomical Department, University Pediatric Hospital, William Soler Ledea, Havana, Cuba

⁵Faculty of Medical Sciences Dr. Enrique Cabrerias, University of Havana, Havana, Cuba

Email address:

caryverd@infomed.sld.cu (C. V. Canizares)

To cite this article:

Caridad Verdecia Canizares, Luis Alexis Graveran Sanchez, Niurka Diaz Zayas, Damian Pineda Fernandez. Pulmonary Metastasis of Ewing's Sarcoma in Pediatric Age: Literature Review and Case Report. *International Journal of Medical Case Reports*. Vol. 1, No. 3, 2022, pp. 21-24. doi: 10.11648/j.ijmcr.20220103.13

Received: June 15, 2022; **Accepted:** July 4, 2022; **Published:** July 20, 2022

Abstract: Ewings sarcoma is a malignant mesenchymal tumor, extremely rare in patients under 10 years of age, being more frequent from the second decade of life. Its annual incidence is low, 1 to 3 cases per year per million children under 15 years of age. The most affected bone sites are: metaphysis of the long bones, Followed frequently by the pelvic bones from 20 to 25%, tumors that affect the axial skeleton have a worse prognosis and affect individuals close to adulthood. The symptoms are common to other bone tumors: intermittent pain and inflammation located in the affected area, and metastases via the hematogenous route to the lung. It appears in patients in the stage of life of greater exercise and changes in the body typical of adolescence. Treatment is based on extensive surgery of the lesion with free section margins whenever the site or location of the tumor allows it, chemotherapy with high-dose drug association, and radiotherapy. More than 90% of these tumors are characterized by a reciprocal translocation of chromosomes 11 and 22, resulting in a novel EWS-FLI1 fusion protein. Because these tumors show only neuroectodermal markers of differentiation, it has been suggested that they arise from neural crest cells. Our goal is to present a case of a patient of only two years of age with stage IV disease at the time of diagnosis, highlighting the value of multidisciplinary teamwork where imaging studies and pathology immunohistochemical techniques play a fundamental role in the diagnosis of the entity.

Keywords: Bone Ewing Sarcoma, Lung Metastasis, Pediatrics

1. Introduction

Ewing's sarcoma (ES) is a malignant neoplasm of mesenchymal origin that affects children and adolescents, with a peak incidence in the second decade of life. The average age being between 13 and 16 years [1, 2]. It was described by the American histopathologist, oncologist, anhematologist James Stephen Ewing in 1921 [1, 2]. The annual incidence is 1-3 cases per million children under 15 years of age. Ewing's sarcoma accounts for about 1.5% of all childhood cancers and is the second most common type of bone sarcoma [1, 2].

It appears in patients in the stage of life of greater exercise

and changes in the body typical of adolescence, so it can be confused at first with bone growth pains, with banal local traumas of exercise in daily activities [1, 3-5].

Clinically, it presents as a picture characterized by intermittent bone pain at the site of the injury, which increases at night and increases in intensity, may be accompanied by increased local volume, in the form of a mass that may be painful on palpation, sometimes It is accompanied by fever and constitutional syndrome due to weight loss, asthenia and anorexia [1, 3, 4].

The most affected bone sites are: metaphysis of the long

bones (around 56%, costal arches approximately 15 to 17%, flat bones 16% and skull between 3 to 4%) [1, 2, 6, 7].

Ewing's sarcoma produces metastases via the hematogenous route to the lung in more than half of the cases, to the bone, brain and bone marrow, less frequently via the lymphatic route to distant nodes. It is good to point out that in most cases these metastases are present from the beginning of the disease [2, 7, 8].

Diagnosis is based on imaging studies: X-rays of the affected limb or site, Computerized Axial Tomography (CAT) and Nuclear Magnetic Resonance Imaging (MRI) [1, 6, 9]. Primary tumor biopsy is mandatory. Definite diagnosis requires histological evaluation and confirmation with cytogenetic or molecular biology techniques. The defining characteristic of these tumors is the presence of a series of chromosomal translocations that culminate in the fusion of the EWSR1 gene, on chromosome 22, with one of several members of the ETS family of transcription factors. The most common of these translocations, t (11; 22) (q24; q12), which fuses the EWSR1 gene with the FLI1 gene on chromosome 11, is present in approximately 90% of cases immunohistochemistry demonstrates CD 99 positive. [9].

Treatment is based on extensive surgery of the lesion with free section margins whenever the site or location of the tumor allows it, chemotherapy with high-dose drug association, and radiotherapy [2, 3, 8, 10].

The prognosis of this variant of tumor depends on age, clinical stage at diagnosis, since the presence of metastases at the time of diagnosis overshadows the prognosis, especially in the lung, causing a low survival rate of around 21% [2, 11], while patients diagnosed early in the initial stages of the disease have a better survival of around 50% [1, 2]. Mortality is high, especially in the first year after diagnosis in cases with lung metastases. Five-year disease-free survival is very low, around 10% to 31% of cases [2, 6, 12].

2. Case Presentation

We present the case of a mestizo female patient from the province of Camaguey, who at 2 years of age begins with an increase in volume in the anterolateral face of the left lower limb, of two months of evolution accompanied by intermittent fever, in her area of health interpret the symptoms as if it were acute osteomyelitis of the tibia, so they sent her to the Pediatric Hospital of her native province they admitted her with a diagnosis of possible osteomyelitis and started antibiotic treatment with phosphocin first intravenously and then orally, also with non-steroidal anti-inflammatory drugs, evolutionarily they did not see clinical improvement and radiographic studies of the lower left extremity were performed, detecting osteolytic lesion and bone destruction. A CT scan is performed, verifying a destructive bone tumor lesion of the proximal third of the anterior face of the left tibia.

Clinically, the visible and palpable tumor lesion in the anteromedial aspect of the upper third of the left lower

extremity continued to increase in size, so the relatives decided to travel to the capital of the country where they were admitted to our hospital in December 2019, studies were completed and a CT scan of the lung is performed, a single metastatic lesion is confirmed in the lower lobe projection of the left lung, without associated respiratory symptoms. The diagnosis was made by surgical biopsy of the tibial bone lesion, yielding the histopathological study: Ewing's sarcoma.

The general physical examination maintained good coloration of the skin and mucous membranes.

Chest: symmetrical with adequate ventilatory movements, without alterations of the vesicular murmur in the lung fields, no rales. Rf: 28xmin.

Cardiovascular: Rhythmic heart tones, not murmurs. HR: 88xmin AT: 90/50

Examination of the lower left extremity below the patella detected a painful tumor lesion of approximately 8 to 12 centimeters in diameter, somewhat painful on palpation, firm consistency, well-defined borders, non-movable.

No peripheral lymph nodes.

Free sensory. No meningeal signs.

Sensory and motor reflexes preserved.

It is discussed in a multidisciplinary team and it is decided to start treatment with high-dose chemotherapy and evaluate at the end of the first 4 cycles VAC/IE (vincristine, cyclophosphamide, doxorubicin alternating with ifosfamide/etoposide, it was evaluated and the response was very poor with only a clinical and imaging reduction of the tumor lesion from 1.5 to 2 cm, it is agreed in Within the tumor committee with the authorization of the parents to perform the surgery in the month of May 2020, the supracondylar amputation of the affected limb was performed, with very good postoperative evolution and healing of the stump.

Pathological anatomy result: Ewing's sarcoma of the upper third of the tibia, with extensive necrosis, bone section edges and soft tissue free of tumor. Immunohistochemical studies showed CD 99 positive.

The postoperative chemotherapy scheme with cytostatic drugs is continued for 6 complete cycles in order to reduce or disappear the metastatic lesion of the left lung, which from the beginning measured 19 mm x 22 mm, thus maintaining that diameter throughout the systemic treatment. which ends in September 2021.

She is studied again at the end of the chemotherapy treatment and the patient maintains a pulmonary metastatic lesion in projection of the lower lobe of the left lung, but with slight growth to 20x28mm in the chest X-ray, but in the CT the lesion was 28x34mm. (Figure 1).

The multidisciplinary team discussed it again and it was agreed to perform the metastasis through the left anteroposterior thoracotomy. On November 4, 2021, she was operated on and a wide resection of the lesion was performed at the level of the lower segment of the lingula of the left lung. (Figure 2).

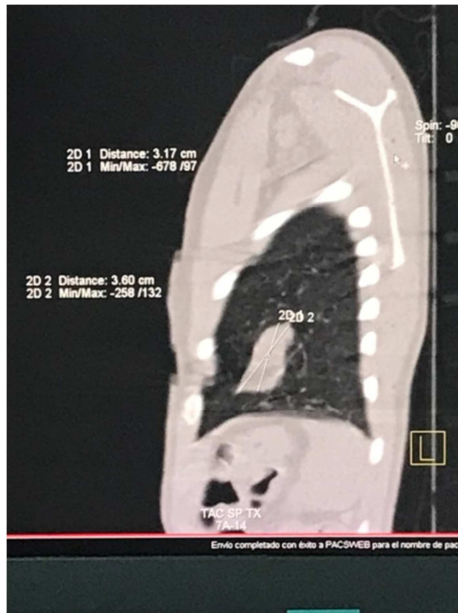


Figure 1. Contrast-enhanced CT scan of the chest sagittal view, where a metastatic lesion of the lower lobe of the left lung is displayed.

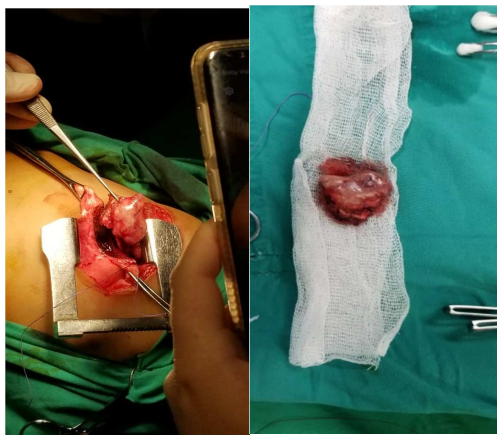


Figure 2. A Wide resection surgery of the left lung metastasis together with adjacent tissue of the lingula where it was inserted. B Resected pulmonary metastatic lesion.

Pathological anatomy result: small blue cell tumor metastasis with mitotic index greater than 10 per field, tumor necrosis index 5%, presence of vascular permeation, histological picture compatible with Ewing Sarcoma metastasis.

The postoperative evolution was good, the wound healed without complications.

He presented fever 11 days after surgery and a mild inflammatory process was found at the base of the left lung without pleural effusion by ultrasound or chest X-rays. He completed antibiotic treatment first with Piperacillin with Tazobactam and Amikacin, but the fever persisted and on the fifth day the antibiotic treatment was changed due to *Staphylococcus epidermididis* growth in blood culture performed to Vancomycin and Meronem, the fever disappearing and he always maintained a very good general condition.

Locoregional radiotherapy of the left lung was then

performed for six sessions during the month of December 2021. The postoperative chemotherapy treatment was completed in the months of January and February 2022. To date, the patient is stable.

Two months after finishing treatment, a positron emission tomography (PEC/CT) scan was performed from the apex of the skull to the middle third of the femurs, which did not reveal abnormal areas of glycolytic hypermetabolism. Conclusions of the study no tumor metabolic lesion was observed at the bone, lung or ganglionic chain level.

This case is brought to collation due to the rarity of this tumor variant in early ages of life, and due to its presentation in an advanced stage of the disease from the beginning (Stage IV). Highlighting the value of surgery in disease control combined with other therapeutic weapons: chemotherapy and ionizing radiation.

3. Discussion

Ewing's sarcoma is a primary malignant bone tumor that is common in children, preceded in frequency by osteosarcoma. [1, 9]. It is a very aggressive tumor, its etiology is unknown, it is more common in males, it is located more common in the lower half of the skeleton [1, 3, 4].

It tends to metastasize early, mainly to the lung. It should be noted that primary lung neoplasms are infrequent in children, they are usually secondary lesions or metastases of malignant solid tumors typical of childhood, and their clinical manifestations are initially confused with an infectious process [2, 5].

There are few case reports of this tumor variant in early life. Izaguirre et al. [3]. reported a 13-year-old patient with Ewing's sarcoma of the left fibula, but in such a young age as in our case it is extremely rare.

The symptoms are common to other bone tumors: intermittent pain and inflammation located in the affected area [2, 4, 9]. Generally, these symptoms are confused with inflammatory processes. In order to establish an early diagnosis of the bone lesion, in addition to the symptoms, imaging studies of the chest X-ray, CT and MRI are required. It is also important to evaluate early for disease recurrence [3, 9-14].

The main treatment weapon for this variant of malignant tumor is surgery with en bloc resection of the tumor and nearby soft tissues or amputation of the limb, in very specific cases limb salvage surgery is proposed [2, 3, 9, 15].

Sánchez Saba et al. [9] in their study of 88 patients diagnosed with Ewing's sarcoma of bone treated with preoperative chemotherapy and limb-sparing surgery, the overall survival rates were 79.5% at 2 years, 69% at 5 years and 64% at 10 years considered that limb-sparing surgery associated with pre- and postoperative chemotherapy should be the treatment for Ewing's sarcoma of bone that meets certain requirements that allow its performance. In our case, it did not meet the necessary requirements and demands for its performance since the disease was metastatic since its diagnosis [9, 10].

Most authors agree that chemotherapy is mandatory for disease control before (neoadjuvant) and after surgery (adjuvant), the most widely used regimens worldwide are VACA (vincristine, actinomycin, cyclophosphamide, doxorubicin) and VAC/IE (vincristine, cyclophosphamide, doxorubicin alternating with ifosfamide/etoposide) [3, 9]. Other protocols are VAI (vincristine – actinomycin – ifosfamide) and VIDE between 6 and 8 cycles. For a definitive diagnosis, histopathological studies with immunohistochemical technique are required, the realization of the CD99 immunomarker is necessary to confirm this entity since it gives us a sensitivity of more than 90% [2, 3, 7, 9, 11].

Definite diagnosis requires histological evaluation and confirmation with cytogenetic or molecular biology techniques. Under the light microscope, Ewing's sarcoma appears as a tumor of small, round, blue cells, with different architectural patterns and variable protein expression, detectable by immunohistochemical techniques [3, 9, 10]. Stéphanie Foulon *et al.* [16] in a study conducted stated that although the role of radiotherapy has been discussed, it demonstrated that the use of radiotherapy helps in local control of the disease and reduction of tumor volume [15-17].

4. Conclusion

We conclude that the multidisciplinary teamwork allowed the control of the disease in our patient, highlighting the essential role of surgery in the control of the disease, together with chemotherapy and locoregional radiotherapy.

References

- [1] Ewing J. Classics in oncology. Diffuse endothelioma of bone. James Ewing. Proceedings of the New York Pathological Society, 1921. *CA Cancer J Clin* 1972; 22: 95-8.
- [2] Ortiz-Escobar A, Monsalvo-Zuleta H, Martínez-Rangel D, Torrenegra-Villalobos J, Bernal-Torres L, *et al.* Ewing's sarcoma in a public children's hospital in Cartagena: case series, 2010-2012. *Scientific Spike* 2014; 11: 87-92.
- [3] Izaguirre G A, Mejía K I, Castro CA, Cárcamo SH, Toledo-M L, Cruz BC. Ewing's Sarcoma with Pulmonary Metastasis in a Pediatric Patient: Case Report. *Archives of Medicine MedPub Journals* 2016; 12 (2): 5 <http://imedpub.com> doi: 10.3823/1290.
- [4] Jiménez SD, Soto FJ, Garro OM, Vega UG. Ewing's sarcoma. *Rev CIE Med* 2014; UCR4: 9-12.
- [5] Cruz S, Azevedo P, Trigueros N, Rodríguez M. Ewing's sarcoma: a rarity in the sinus region. *Otorrinolaringol Act* 2015; Esp 66: 171-174.
- [6] Hernandez EH, Mosquera CG, Quintero MO, Hernandez CI. Ewing's sarcoma. *Magazine Medical Archive of Camagüey* 2013; 17: 623-640.
- [7] Albergo JI, Gaston CL, Laitinen M, *et al.* Ewing's sarcoma: only patients with 100% of necrosis after chemotherapy should be classified as having a good response. *Bone Joint J* 2016; 98-B: 1138-44.
- [8] Argentine Hospital Oncopediatric Registry. In: <http://www.msal.gov.ar/inc/epidemiologia-y-registros/roha/>; accessed September 2018.
- [9] Sanchez-saba J, Abrego MO, Albergo JI, Farfalli GI, Aponte-Tinao LA, Ayerza MA, *et al.* Sarcoma de Ewing óseo. Enfoque multidisciplinario y resultados oncológicos en 88 pacientes. *Medicina* 2020; 80 (1).
- [10] Gaspar N, Hawkins DS, Dirksen U. Ewing sarcoma: current management and future approaches through collaboration. *J Clin Oncol* 2015; 33: 3036-40.
- [11] Werier J, Yao X, Caudrelier J M. A systematic review of optimal treatment strategies for localized Ewing's sarcoma of bone after neo-adjuvant chemotherapy. *Surg Oncol* 2016; 25: 16-23.
- [12] Bosma SE, Ayu O, Fiocco M, Gelderblom H, Dijkstra PDS. Prognostic factors for survival in Ewing sarcoma: A systematic review. *Surg Oncol* 2018; 27: 603-10.
- [13] Miller BJ, Gao Y, Duchman KR. Does surgery or radiation provide the best overall survival in Ewing's sarcoma? A review of the National Cancer Data Base. *J Surg Oncol* 2017; 116: 384-90.
- [14] Verma V, Denniston KA, Lin CJ, Lin C. A Comparison of Pediatric vs. Adult Patients with the Ewing Sarcoma Family of Tumors. *Front Oncol* 2017; 7: 82.
- [15] Albergo JI, Gaston CLL, Parry MC, Laitinen MK, Jeys L M, Abudu A T, *et al.* Risk analysis factors for local recurrence in Ewing's sarcoma: when should adjuvant radiotherapy be administered? *Bone Joint J* 2018; 100-B: 247-55.
- [16] Foulon S, Brennan B, Gaspar N, Dirksen U, Jeys L, Cassoni A, *et al.* Can postoperative radiotherapy be omitted in localised standard-risk Ewing sarcoma? An observational study of the Euro-E.W.I.N.G group. *Eur J Cancer* 2016; 61: 128-36.
- [17] Werier J, Yao X, Caudrelier J-M. Evidence-based guideline recommendations on treatment strategies for localized Ewing's sarcoma of bone following neo-adjuvant chemotherapy. *Surg Oncol* 2016; 25: (2): 92-7. doi: 10.1016/j.suronc.2016.03.006. Epub 2016 Mar 25.