

Senegalese Experience of Pseudo Hypoparathyroidism About Three Cases at the Department of Neurology in Fann Teaching Hospital

Halladain Mpung Mansoj*, Adjaratou Dieynabou Sow, Moustapha Ndiaye

Department of Neurology, Cheikh Anta Diop University, Fann Teaching Hospital, Dakar, Senegal

Email address:

edolens@gmail.com (Halladain Mpung Mansoj)

*Corresponding author

To cite this article:

Halladain Mpung Mansoj, Adjaratou Dieynabou Sow, Moustapha Ndiaye. (2023). Senegalese Experience of Pseudo Hypoparathyroidism About Three Cases at the Department of Neurology in Fann Teaching Hospital. *International Journal of Medical Case Reports*, 2(4), 28-35. <https://doi.org/10.11648/j.ijmcr.20230204.12>

Received: October 3, 2023; **Accepted:** November 1, 2023; **Published:** December 18, 2023

Abstract: Pseudohypoparathyroidism is a group of rare, related and highly heterogeneous disorders characterized by target organ resistance to the action of parathyroid hormone. Pseudohypoparathyroidism and related disorders are caused by genetic and/or epigenetic changes resulting in downregulation of a cyclic adenosine mono phosphate generator primarily linked to the GNAS gene, patients who have experienced hormonal parathyroid (hypocalcemia and hyperphosphatemia resistant to parathyroid hormone with characteristic skeletal and developmental changes. Multiple transcript variants encoding different isoforms have been found for this gene. Mutations in this gene result in pseudohypoparathyroidism type 1a, pseudohypoparathyroidism type 1b, hereditary osteodystrophy; Albright, pseudohypoparathyroidism, McCune-Albright syndrome, progressive bone heteroplasia, polyostotic fibrous dysplasia of bone, and certain pituitary tumors Here we report a series of 3 cases carrying pseudohypoparathyroidism, their sociodemographic, clinical and paraclinical aspects as well as therapeutic.

Keywords: Pseudohypoparathyroidism, PTH Resistance, Subcutaneous Ossifications, Brachydactyly

1. Introduction

The term pseudohypoparathyroidism (PHP) was first introduced in 1942 by Albright to describe patients who presented with hormonal parathyroidism (PTHb-resistant hypocalcemia and hyperphosphatemia with characteristic skeletal and developmental changes. Pseudohypoparathyroidism (PHP) is a group of rare, related and highly heterogeneous disorders characterized by end-organ resistance to the action of parathyroid hormone (PTH). PHP and related disorders are caused by genetic and/or epigenetic changes resulting in downregulation of a cyclic adenosine mono phosphate (cAMP) generator, mainly linked to the GNAS gene [57]. The two main subtypes of PHP are types 1a and 1b (PHP-1a, PHP-1b) and are caused by molecular alterations within or upstream of the GNAS gene. [57]. Multiple transcript variants encoding different isoforms have been found for this gene. Mutations in this gene result

in pseudohypoparathyroidism type 1a, pseudohypoparathyroidism type 1b, Albright hereditary osteodystrophy, pseudohypoparathyroidism, McCune-Albright syndrome, progressive bone heteroplasia, polyostotic fibrous dysplasia of bone, and some pituitary tumors [58].

2. Methodology

2.1. Type and Period of Study

This is a study of clinical cases.

2.2. Collection Instruments

The entry register and patient files constituted our sources of information.

2.3. Data Entry

We used OFFICE 2019 for data entry.

For references we use the Zotero software: 6.0.26 is according to Vancouver (UCAD FMPO Method).

2.4. Study Population

Our study concerned all children consulted in the pediatric neurology outpatient clinic (Fann and Albert Royer hospital).

2.5. Inclusion Criteria

All files of consultants with a diagnosis of pseudo hypoparathyroidism.

2.6. Exclusion Criteria

An incomplete or non-usable file was excluded from the study.

2.7. Ethical Considerations

Anonymity will be respected when filling out the data collection sheets.

2.8. Difficulties Encountered

During our study we encountered some difficulties such as:

The non-computerization of data;

Lack of financial means for additional analyzes.

3. Result or Clinical Case Study

Patient number 1

Demographics K.F age: 21

Gender: Male.

1) Presentation of symptoms.

Episode of tonic contracture at 10 -12 weeks appears focal motor seizures of brave Jacksonian types with deviations of the head and eyes.

2) Medical and family history.

a. Difficult delivery (for “days”).

b. Myoclonus in infancy

c. Acrie at birth

d. Birth weight 6Kg

e. Sitting at 12 Months

f. Language at 2 years old

g. Repeating the 5th grade

3) Comorbidities (first cousin followed in a local hospital center) and his epileptic brother.

4) Physical examination.

a. Macrocrania

b. No motor or sensory deficit

c. Rot abolition

d. Hollow foot

5) Diagnostic approach.

Imaging.

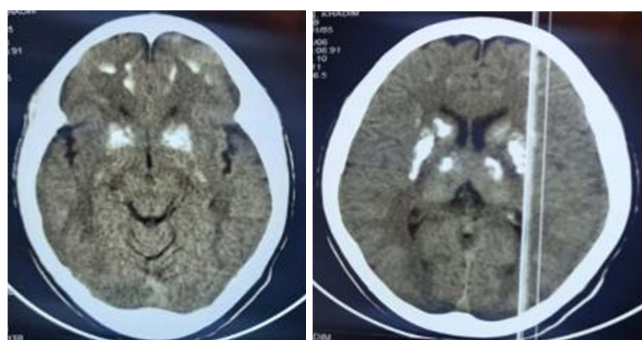


Figure 1. Brain CT: Calcification of the lenticular nuclei, caudate nuclei associated with parietal cortico-subcortical calcifications.

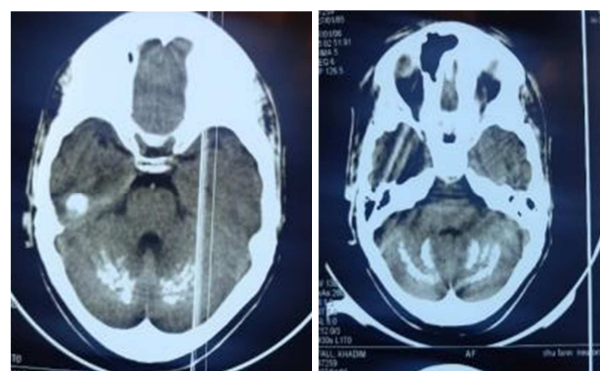

Figure 2. Brain CT. Axial section Significant calcifications of the bulbar olives.

1) WAKE EEG: Presence of paroxysmal activities and diffuse theta activities predominantly bi fronto-temporal compatible with focal epilepsy.

2) Normal ENMG.

3) Laboratory examination:

a. Normal urea,

b. Normal creatinine

c. Normal fasting blood sugar

d. Serum calcium 59 mg/l (81-104).

e. Phosphoremia 9.8 mg/l (2.7-4.50 mg/l).

f. Intact parathyroid hormone: 75 ng/l; 3a 51

4) Treatment.

Phenobarbital with seizure control for a few months; then reappears

Patient number: 2

Demographics SF age: 11 years old

Gender: Male.

1) Presentation of symptoms.

Episode of generalized tonic-clonic seizures during TCE

At 8 years old, onset of focal brachiofacial motor seizures (dystonia of the right upper limb, ocular revulsions).

2) Medical and family history.

a. Cesarean/breech delivery

b. Acrie at birth

c. Birth weight 5-6Kg.

d. 3 Repeat: CP and CI.

Comorbidities (first cousin followed in a local hospital center). several cases in siblings including his brother so high.

3) Physical examination.

Normal psychomotor development.

- a. No motor or sensory deficit
- b. Rot abolition
- c. Hollow foot, craniofacial dysmorphism

4) Diagnostic approach.

Imaging. Brain CT axial section

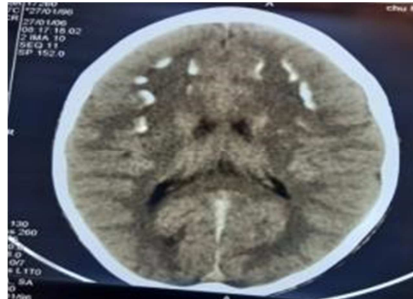

Figure 3. Calcification of lenticular nuclei and fronto-parietal subcortical regions.

Imaging. Brain CT axial section

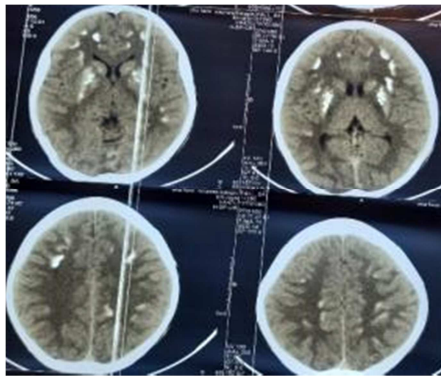


Figure 4. Calcification of lenticular nuclei and fronto-parietal subcortical regions.

WAKE EEG: presence of diffuse paroxysmal activities compatible with focal epilepsy.

5) Laboratory examination;

- a. Serum creatinine: normal
- b. Urea: normal
- c. Calcemia: 49 mg/l (81-104).
- d. Phosphoremia: 9.8 mg/l (2.7-4.50 mg/l).
- e. Intact parathyroid hormone: 221 ng/l: 3 to 51

6) Treatment.

Phenobarbital 50 mg, with relief of seizures for a few months; then reappears

Patient number: 3

Demographics M.B age: 12 years old.

Gender: Male.

1) Presentation of symptoms.

Motor deficits of all four limbs associated with a language disorder and generalized tonic-clonic seizures.

2) Medical and family history.

- a. Normal delivery.
- b. Acrie at birth
- c. Birth weight 3 kg
- d. Sitting at 14 Months

e. Language at 2 years old

3) RAS comorbidities

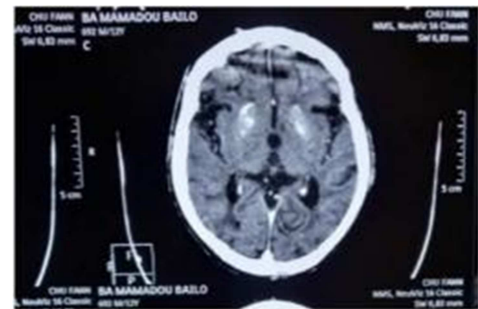
4) Physical examination.

- a. Motor aphasia
- b. A flasco-spasmodic motor deficit of all four with segmental muscle strength of 4/5 in all four limbs.
- c. Strong tendon reflexes in all four limbs
- d. Proximal-distal amyotrophies of all four limbs
- e. Cutaneous-plantar reflexes in extension bilaterally.

Imaging. Brain CT axial section

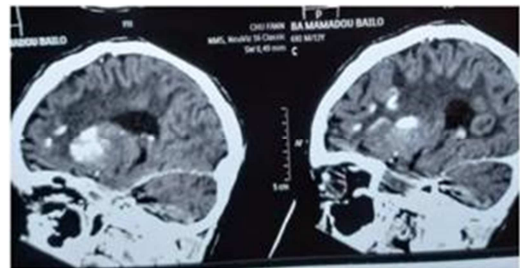

Figure 5. Calcification of the lenticular nuclei and frontal subcortical regions.



Slow wave bursts notched peak in bi-parieto -temporal.

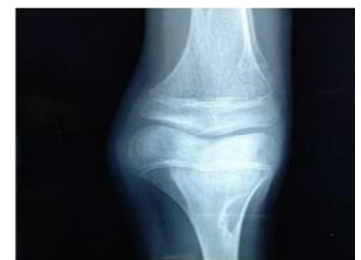
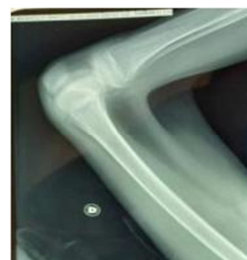
Figure 6. Bone X-ray of tea knees: showing bone hyper transparency and multiple cortical gaps.

Blood:

- a. Calcium: 98 (90-107 mg / l) normal
- b. Magnesium: 20 normal
- c. Creatinine: normal
- d. Protein: 71 normal
- e. ASAT AT: 29 normal
- f. ALT: 17 normal
- g. Phosphoremia: 31.8 [27 - 45 mg / l] normal
- h. Copper 1657 mg / day [794 - 2023] normal
- i. Intact parathyroid hormone: 160.1 ng/l: [1.59 - 7.21].

Vit D (25 - 0H) <8.1 mg/ml Deficiency <10 mg/ml normal

Diagnosis of pseudohypoparathyroidism complicated by

rickets.

4. Discussion

Parathyroid hormone is the main hormone that maintains serum levels of calcium and phosphorus in the body. The functions of parathyroid hormone mainly include distal tubular resorption of calcium, bone resorption, increased synthesis of 1,25 hydroxy vitamin D, thus leading to enhanced intestinal absorption of calcium [26, 44]. AHO is an inherited metabolic disorder typically presented by a constellation of characteristic physical features such as obese build, short stature, and brachydactyly. AHO, when associated with target organ resistance to hormones like parathyroid hormone, gonadotropins and thyroid stimulating hormone (TSH), is called pseudo hypoparathyroidism (PHP) [50]. Genetic studies carried out to determine the etiology of AHO revealed a mutation in the *GNAS1* gene located at 20q13-11 as the gene responsible for the disease [14]. PHP is rare and hereditary hormone resistance syndrome was first reported in 1942 by Albright *et al.* The pathophysiology of PHP involves the dysfunction of parathyroid hormone (PTH) receptors in peripheral target organs or in their signal transduction pathways [32]. There are two types of PHP which are classified based on the reaction of renal proximal convoluted tubules to bovine PTH extract and characterized by resistance to PTH via deficiency of glutamine synthase (GS) activity in various types of cells, which is different with hypoparathyroidism in the elevated or normal serum PTH level. And so far, numerous mutations in the gene coding for *Gsa* (*GNAS*) have been reported [33]. For background: In both of our reported cases there is a family history of similar seizures in the family our data is consistent with the results reported by Marguet *et al.* [36] on the contrary for the cases presented by Monica Gomes *et al* did not have a family history [18]. Demographic data of our patients In our series all patients are male. A male predominance in the literature had been found in the cases reported by: Ji Eun Jun *et al*; Abhijit Swami *et al*; H Hosojima, *et al*; K Yamada *et al* and SW De Silva *et al* [25, 51, 23, 54, 8].

This is contrary to the literature reported by the studies carried out: Davies and Hughes, Fitch N *et al.*, Sunder and Singh, and Esel Ertugrul *et al.*, [50, 6, 7, 12] who found a female predominance in their case series. The manifestations common to our three patients were epileptic seizures. Our data is consistent with Najim *et al* [41], S *et al* [46] and Del Monte *et al* [9]. In the literature, numerous studies have demonstrated that calcification of the basal ganglia plays an important role in the propagation and modulation of epileptic seizures. While some have argued that basal ganglia calcification is a seizure propagation pathway that can suppress the EEG signatures and behavioral expression of epileptic seizures, others argue that basal ganglia calcification circuits central gray cells can remotely inhibit epileptic seizures [4]. Advancing these theories, calcifications in the basal ganglia could disrupt inhibitory circuits, thereby causing epileptic seizures in patients. Until

now, no study has been able to demonstrate that these cortical deposits are directly linked to epileptogenicity. Our patients were diagnosed with symptomatic epilepsy, both secondary to and caused by PHP. Symptomatic epilepsies consisted of two types of seizures: focal seizures with altered consciousness and focal to bilateral tonic-clonic seizures, in accordance with the 2017 classifications of the International League Against Epilepsy (ILAE) [48]. Convulsive seizures could be due to extremely intense stimuli that caused conduction through the subcortical thalamic nuclei and basal ganglia to neurons, resulting in seizure episodes [56]. Gamma-aminobutyric acid (GABA), an essential inhibitory neurotransmitter that reduces neuronal firing in the brain, is influenced by the extracellular concentration of calcium ions. A reduction in this concentration decreases the probability of release of GABA-containing synaptic vesicles, which, in turn, disinhibits the postsynaptic potential. This is in addition to and secondary to the overactivation of dopamine in the striatum [52]. In Pseudo Hypoparathyroidism hypocalcemia, hyperphosphatemia and elevated PTH concentrations lead to G protein dysfunction which can impair renal calcium resorption, thereby decreasing GABA ergic inhibition. This increased excitability leads to epileptic seizures [45].

This suggests that all these patients with multi-resistant epilepsy should benefit from screening for pseudohypoparathyroidism.

Two of our patients had focal seizures associated with dystonic manifestations of the upper limb as well as a backward movement of the head. The focal seizure may be due to the epileptogenic nature of cortical calcification. Although hypocalcemia alone can cause epileptic seizures, focal metabolic seizures are rare. The medical treatment of epileptic seizures from our series the patients benefited from phenobarbital with secondary aggravation in the literature secondary aggravations linked to the use of phenobarbital would be due to the induction of hypocalcemia [3]. On the EEG the irritative signs predominated in the fronto-temporal and only one of our patients had diffuse irritative signs. The literature data reporting the presence of interictal points were multifocal in nature and predominated in the left (72.3%) and right (27.7%) frontal temporal regions. This could be due to low serum calcium, but also to cortical calcium deposition, as left temporal tips were most often correlated with left temporal calcification. During the critical phase, the seizure began with a right somatosensory aura followed by a dystonic posture of the left limb and a right head turning and staring. The somatosensory aura in the right leg suggests that critical symptomatogenic areas may be located more cortically than subcortically. We know that the somatosensory aura mainly originates from the contralateral postcentral gyrus, but also sometimes from the ipsilateral secondary somatosensory area or the temporal cortices. [13]. According to the semiological localization previously studied, a successive dystonic posture of the left limb accompanied by a rotation of the right head suggests the critical focus is in the right hemisphere. Critical EEG findings of delta to theta waves with peak activity in the right hemisphere, particularly

in the right temporal lobe, also support this hypothesis.

Intracranial calcifications with a calcium concentration of 30% or less will cause T1 hyperintensity, but at higher concentration the signal intensity decreases. [16] In our series all three cases presented intracerebral calcification, our results are similar with only the literature notably that of Kim et al [27] and one and two of our patients had a pallido striatal localization Manabe et al we find the similar result of pallido strialle localization [31]. A cerebellar location on one of our patients, particularly in the cerebellar hemisphere. De Silva et al reported a case of cerebellar calcification. [8]. The intracranial calcification in the patient is consistent with a diagnosis of Fahr syndrome.; however, in the literature Walase et al found extensive white matter lesions that were associated with vascular calcification [24]. The strong contrast between the density of small deposits in gray matter and white matter may be due to the fact that capillaries are more densely distributed in gray matter. [20, 5]. In addition to striopallidodentate calcinosis, such white matter lesions may cause neuropsychiatric symptoms walase et al clarified continuous areas of vascular calcification from the basal ganglia through white matter to the cortices [24].

There appears to be a close correspondence between the extent of vascular calcification and the course of deep penetrating cerebral arteries [39]. For other authors, vascular calcification resulted from passive precipitation of calcium in a matrix containing mucopolysaccharides. [62]. Several anatomical observations support the role of pericytes in brain calcification, [28] and genetic abnormalities linked to abnormalities in pericyte function have recently been implicated in the pathogenesis of primary familial brain calcification. [60].

One in our series had signs of spinal cord compression; notably a tetra paresis; sphincter disorder and pyramidal syndrome of the four limbs; in the literature, spinal cord injury, spinal cord compression was reported by PJ Goadsby et al [17], by li et al. [27], Yamamoto et al [55] and Gibber et al. [15]. Spinal cord compression could be explained by stenosis which develops in patients with PHP secondary to ectopic ossification. The propensity for soft tissue ossification, including ossification of the anterior and/or posterior longitudinal ligaments and the ligamentum flavum and hypertrophic in patients with PHP, is thought to lead to compressive overgrowth in the spinal canal. Ossification of the paravertebral ligaments is a common radiographic finding in patients with severe hypoparathyroidism [2]; abnormal PTH metabolism is involved, although the mechanism by which ectopic ossification occurs has not yet been elucidated. In addition to compression by ectopic ossification, other patients in the literature have presented with considerable congenital stenosis of the medullary canal. It is hypothesized that congenital narrowing of the spinal canal in patients with HPH may be secondary to premature closure of the physes, resulting in a truncated anteroposterior diameter of the spinal canal [43]. As a cognitive manifestation, regression and cognitive delay in all three of our patients. In 1986, Farfel and Friedman [11] reported that reductions in Gas levels

were associated with cognitive impairment, with 47–75% of PHP1A patients having intellectual disability. Twenty years later, the estimate was almost 79% of individuals affected [40]. Cognitive deficits range from minimal learning disabilities to severe impairments [59]. In a recent study comparing siblings and age-matched controls, 16 PHP1A children had significantly lower IQ scores (25% composite IQ <70) for both verbal and nonverbal IQ. There were also deficits in executive and adaptive functions and ADHD [61]. Interestingly, studies in mice demonstrated that females with a maternally inherited mutation neglected their young, resulting in mortality of almost 80% in the young before weaning, unlike those carrying a hereditary paternal mutation, which presented normal maternal behavior. Abnormalities in olfaction and hearing have also been reported in PHP1A [10], suggesting the involvement of GNAS imprinting in other parts of the CNS. Overall, cognitive and behavioral problems can lead to difficulty living independently in adulthood, and enormous support and support from the medical team is needed for patients and their families to long term. Confirmation of the diagnosis of hereditary Albright osteodystrophy is done by the parathyroid hormone test [36] which makes it possible to evaluate the peripheral receptivity of target tissues to exogenous PTH and thus define resistance to PTH in the absence plasma and urinary response markers. It is carried out by the injection of 100 U/m² of exogenous PTH, then the measurement of the plasma cAMP level at T0, T5, T10, T60 associated with a urinary evaluation. The plasma response is considered normal if the peak level is greater than 8 times the base level. We were unable to perform this test in our patient due to lack of technical means. For the diagnosis of pseudo hypoparathyroidism on biological levels we found hypocalcemia, hyperphostamia and a high serum level of parathyroid hormone in our three patients and one of them. our series had a decrease in vitamin D levels. Giovanna Mantovani et al. in the literature found the association of hypocalcemia, hyperphosphatemia and high serum PTH levels in the absence of vitamin D deficiency, abnormal magnesium levels and renal insufficiency. [33]. Several studies reported that decreased serum 25(OH)D levels and impaired bone metabolism were associated with AED treatment in children [38]. Many AEDs are known to be inducers of hepatic cytochrome P450 metabolism, leading to increased hepatic metabolism of vitamin D. Some authors recommend monitoring vitamin D status in children taking antiepileptic medications, particularly those receiving polypharmacotherapy [42]. In our patient, we thought that in addition to an insufficient intake of vitamin D, the use of anti-epileptic drugs could have led to a worsening of the vitamin D deficiency.

In the appropriate context, a patient may be suspected of having PHP when very young, based on hyperphosphatemia and elevated PTH levels, which usually precede hypocalcemia. [53].

The genetic study makes it possible to confirm the diagnosis by looking for a mutation in the GNAS1 gene [19].

Once diagnosed, PTH resistance should be treated with

activated forms of vitamin D, for example calcitriol or alfacalcidol, to increase serum calcium levels and thereby reduce PTH levels.

The authors recommend targeting a serum calcium level in the low normal range and not normalizing the serum PTH concentration, in order to avoid the risk of hypercalcemia and/or hypercalciuria. PTH levels should be maintained at the upper limit or slightly above the reference range (e.g., 50 to 150 pg/ml), because the distal renal nephron remains sensitive to PTH and can reabsorb calcium, reducing thus the risk of hypercalciuria. Vitamin D analogues can be started in infants when PTH increases (eg, 100 to 150 pg/ml), before hypocalcemia develops. Calcium intake should follow age-appropriate guidelines through a regular diet or supplements.

Severe hyperphosphatemia may be treated with oral phosphate binders other than CaCO_3 , if necessary. Since cholecalciferol treatment helps increase calcium absorption in hypocalcemic patients, [22] we suggest maintaining serum 25(OH) vitamin D levels within normal limits.

Adequate management of PTH resistance to reduce the calcium-phosphate product to less than 55 may reduce the development or worsening of lens and brain calcifications, but will of course have no effect on heterotopic ossification (see previously). Treatment of PTH resistance and functional hypoparathyroidism requires regular monitoring of serum levels of calcium, phosphorus, PTH, monitoring of urinary renal calcium excretion (<4 mg/kg per day in adults. child) and renal function. Most patients with PHP1A are not at risk of developing renal calcifications [21] unless they are overtreated, thereby increasing the risk of developing hypercalciuria [37]. Patients with hypothyroidism due to TSH resistance should receive oral thyroxine and have their thyroid function assessed regularly. Patients with PHP and short stature or reduced growth velocity should be evaluated for growth hormone (GH) deficiency. Although we lack long-term data to formally recommend GH treatment in patients with PH and short stature, short-term results and small series have provided encouraging outcomes for patients. [35]. Dietary and lifestyle measures should be implemented at the time of diagnosis, regardless of body mass index, to prevent the development of obesity and metabolic complications. Weight control can be very difficult because obesity is partly the result of decreased resting energy expenditure and patients may not respond to the standard approach of calorie restriction. There is currently no specific therapy for heterotopic ossifications. Small ossifications usually do not progress and do not require treatment. Ossifications that cause pain and/or irritation can be surgically removed unless a large area of skin is involved. [1, 47]. Nonsteroidal anti-inflammatory drugs, thiosulfates or bisphosphonates have been sporadically reported for the treatment of extensive ossifications. [47, 30]. Large studies are, however, necessary to evaluate the effectiveness of these drugs. Regular mobilization of the limbs and physiotherapy are necessary when ossifications surround the joints. [34]. Future innovative therapies for patients with HPH may

include phosphodiesterase inhibitors (e.g., theophylline) aimed at increasing intracellular cAMP levels and a melanocortin receptor agonist. [49].

5. Conclusion

Pseudohypoparathyroidism is characterized by resistance to parathyroid hormone (PTH) and therefore this condition mimics hypoparathyroidism with hypocalcemia and hyperphosphatemia. There are several subtypes depending on the signaling deficit associated with PTH action. The symptoms of this disease are similar to those of hypoparathyroidism; the neurological clinical manifestations include: Intracerebral calcification, convulsive seizures, higher function disorders, neurogenic syndrome. Other non-neurological manifestations include subcutaneous ossifications, brachydactyly, resistance to thyroid-stimulating hormone, short stature and early-onset obesity.

Molecular genetic and/or epigenetic testing is recommended. PTH resistance and secondary hyperparathyroidism should be managed to prevent hypocalcemia and increased bone resorption, respectively.

The care is multidisciplinary for children and adults.

Treatment includes supplementation with calcium, 1,25-dihydroxycholecalciferol and vitamin D2.

References

- [1] Adam MP, Mirzaa GM, Pagon RA, Wallace SE, Bean LJ, Gripp KW, et al., eds. *GeneReviews®*. Seattle (WA): University of Washington, Seattle; 1993.
- [2] Boody BS, Lendner M, Vaccaro AR. *Ossification of the posterior longitudinal ligament in the cervical spine: a review*. Int Orthop. 2019; 43 (4): 797-805.
- [3] Chaabène A, Kamoun F, Charfi N, Triki C, Abid M, Mhiri C. *Hypocalcemic epileptic seizures: study of 7 cases*. Epilepsies. 2006; 18 (3): 149-154.
- [4] Cho D, Min B, Kim J, Lee B. *EEG-based prediction of epileptic seizures using phase synchronization elicited from noise-assisted multivariate empirical mode decomposition*. IEEE Trans Neural Syst Rehabil Eng. 2016; 25 (8): 1309-1318.
- [5] Craigie EH. *On the relative vascularity of various parts of the central nervous system of the albino rat*. J Comp Neurol. 1920; 31 (5): 429-464.
- [6] Davies SJ, Hughes HE. *Imprinting in Albright's hereditary osteodystrophy*. J Med Genet. 1993; 30 (2): 101-103.
- [7] De Silva SW, De Silva SDN, De Silva CE. *A patient with extensive cerebral calcification due to pseudohypoparathyroidism: a case report*. BMC Endocr Disord. 2019; 19 (1): 142.
- [8] Del Monte P, Cuttica CM, Marugo A, Foppiani L, Audenino D, Godowicz TT, et al. *Unrecognized Pseudohypoparathyroidism Type 1A as a Cause of Hypocalcemia and Seizures in a 64-Year-Old Woman*. Case Rep Endocrinol. 2019; 2019: 8456239.

- [9] Doty RL, Fernandez AD, Levine MA, Moses A, McKeown DA. *Olfactory Dysfunction in Type I Pseudohypoparathyroidism: Dissociation from Gs α Protein Deficiency**. J Clin Endocrinol Metab. 1997; 82 (1): 247-250.
- [10] Farfel Z, FRIEDMAN E. *Mental deficiency in pseudohypoparathyroidism type I is associated with Ns-protein deficiency*. Ann Intern Med. 1986; 105 (2): 197-199.
- [11] Fitch N, Opitz JM, Herrmann J. *Albright's hereditary osteodystrophy: a review*. Am J Med Genet. 1982; 11 (1): 11-29.
- [12] Foldvary-Schaefer N, Unnwongse K. *Localizing and lateralizing features of auras and seizures*. Epilepsy Behav. 2011; 20 (2): 160-166.
- [13] Garavelli L, Pedori S, Zanacca C, Caselli G, Loidice A, Mantovani G, et al. *Albright's hereditary osteodystrophy (pseudohypoparathyroidism type Ia): clinical case with a novel mutation of GNAS1*. Acta Biomed. 2005; 76 (1): 45-48.
- [14] Gibberd FB. *Spinal cord compression associated with pseudohypoparathyroidism*. JR Soc Med. 1990; 83 (7): 477.
- [15] Ginat DT, Meyers SP. *Intracranial Lesions with High Signal Intensity on T1-weighted MR Images: Differential Diagnosis*. RadioGraphics. 2012; 32 (2): 499-516.
- [16] Goadsby PJ, Lollin Y, Kocen RS. *Pseudopseudohypoparathyroidism and spinal cord compression*. J Neurol Neurosurg Psychiatry. 1991; 54 (10): 929-931.
- [17] Gomes MF, Camargo AMA, Sampaio TA, Graziozi MAO, Armond MC. *Oral manifestations of Albright hereditary osteodystrophy: a case report*. Rev Hosp Clinicas. 2002; 57: 161-166.
- [18] Goswami M, Verma M, Singh A, Grewal H, Kumar G. *Albright hereditary osteodystrophy: A rare case report*. J Indian Soc Pedod Prev Dent. 2009; 27 (3): 184.
- [19] HN, MA, TN, TH, ZZ. *The fundamental architecture of the microvasculature of the basal ganglia and changes in senility*. Neuropathology. 1998; 18 (1): 47-54.
- [20] Hansen DW, Nebesio TD, DiMeglio LA, Eugster EA, Imel EA. *Prevalence of Nephrocalcinosis in Pseudohypoparathyroidism: Is Screening Necessary?* J Pediatr. 2018; 199: 263-266.
- [21] Heaney RP, Barger-Lux MJ, Dowell MS, Chen TC, Holick MF. *Calcium Absorptive Effects of Vitamin D and Its Major Metabolites I*. J Clin Endocrinol Metab. 1997; 82 (12): 4111-4116.
- [22] Hosojima H, Morimoto S, Uchida K, Yamamoto I, Kigoshi T, Azukizawa S, et al. *Pseudohypoparathyroidism (PHP) type II and selective hypoaldosteronism in a patient with retinitis pigmentosa*. Jpn J Med. 1984; 23 (2): 144-148.
- [23] Iwase T, Yoshida M, Hashizume Y, Yazawa I, Takahashi S, Ando T, et al. *Intracranial vascular calcification with extensive white matter changes in an autopsy case of pseudopseudohypoparathyroidism*. Neuropathology. 2019; 39 (1): 39-46.
- [24] Jun JE, Park SY, Jeong IK, Hwang YC, Ahn KJ, Chung HY. *Delayed diagnosis of pseudohypoparathyroidism type Ia with rare hypothyroidism since childhood*. Oxf Med Case Rep. 2022; 2022 (8): omac080.
- [25] Kapoor S, Gogia S, Paul R, Banerjee S. *Albright's hereditary osteodystrophy*. Indian J Pediatr. 2006; 73: 153-156.
- [26] Kim YS, Park J, Park Y, Hwang K, Koo DL, Kim D, et al. *Intracranial Cortical Calcifications in a Focal Epilepsy Patient with Pseudohypoparathyroidism*. J Epilepsy Res. 2016; 6 (1): 31-35.
- [27] Kobayashi S, Yamadori I, Miki H, Ohmori M. *Idiopathic nonarteriosclerotic cerebral calcification (Fahr's disease): an electron microscopic study*. Acta Neuropathol (Berl). 1987; 73 (1): 62-66.
- [28] Li P, Huang L, Zhao Z, Ye X, Liu Z. *Spinal-cord compression related to pseudohypoparathyroidism*. J Clin Neurosci Off J Neurosurg Soc Australas. 2011; 18 (1): 143-145.
- [29] Macfarlane RJ, Han Ng B, Gamie Z, Masry MAE, Velonis S, Schizas C, et al. *Pharmacological treatment of heterotopic ossification following hip and acetabular surgery*. Expert Opin Pharmacother. 2008; 9 (5): 767-786.
- [30] Manabe Y, Araki M, Takeda K, Yokota S, Kimura T. *Pseudohypoparathyroidism with striopallidentate calcification—a case report and review of the literature*. Jpn J Med. 1989; 28 (3): 391-395.
- [31] Mantovani G. *Pseudohypoparathyroidism: Diagnosis and Treatment*. J Clin Endocrinol Metab. 2011; 96 (10): 3020-3030.
- [32] Mantovani G, Bastepe M, Monk D, de Sanctis L, Thiele S, Usardi A, et al. *Diagnosis and management of pseudohypoparathyroidism and related disorders: first international Consensus Statement*. Nat Rev Endocrinol. 2018; 14 (8): 476-500.
- [33] Mantovani G, Ferrante E, Giavoli C, Linglart A, Cappa M, Cisternino M, et al. *Recombinant Human GH Replacement Therapy in Children with Pseudohypoparathyroidism Type Ia: First Study on the Effect on Growth*. J Clin Endocrinol Metab. 2010; 95 (11): 5011-5017.
- [34] Marguet C, Mallet E, Basuyau JP, Martin D, Leroy M, Brunelle P. *Clinical and biological heterogeneity in pseudohypoparathyroidism syndrome. Results of a multicenter study*. Horm Res. 1997; 48 (3): 120-130.
- [35] Matos V, van Melle G, Boulat O, Markert M, Bachmann C, Guignard JP. *Urinary phosphate/creatinine, calcium/creatinine, and magnesium/creatinine ratios in a healthy pediatric population*. J Pediatr. 1997; 131 (2): 252-257.
- [36] Mintzer S, Boppana P, Toguri J, DeSantis A. *Vitamin D Levels and Bone Turnover in Epilepsy Patients Taking Carbamazepine or Oxcarbazepine*. Epilepsy. 2006; 47 (3): 510-515.
- [37] Moody DM, Bell MA, Challa VR. *Features of the cerebral vascular pattern that predict vulnerability to perfusion or oxygenation deficiency: an anatomic study*. Am J Neuroradiol. 1990; 11 (3): 431-439.
- [38] Mouallem M, Shaharabany M, Weintrob N, Shalitin S, Nagelberg N, Shapira H, et al. *Cognitive impairment is prevalent in pseudohypoparathyroidism type Ia, but not in pseudopseudohypoparathyroidism: possible cerebral imprinting of Gs α* . Clin Endocrinol Oxf. 2008; 68 (2): 233-239.

- [39] Najim MS, Ali R, Awad M, Omer A. *Pseudohypoparathyroidism presenting with seizures: a case report and literature review*. Intractable Rare Dis Res. 2020; 9 (3): 166-170.
- [40] Nettekoven S, Ströhle A, Trunz B, Wolters M, Hoffmann S, Horn R, et al. *Effects of antiepileptic drug therapy on vitamin D status and biochemical markers of bone turnover in children with epilepsy*. Eur J Pediatr. 2008; 167 (12): 1369-1377.
- [41] Okada K, Iida K, Sakusabe N, Saitoh H, Abe E, Sato K. *Pseudohypoparathyroidism-associated spinal stenosis*. Spine. 1994; 19 (10): 1186-1189.
- [42] PRENTICE R. J. *Pseudohypoparathyroidism: a case report*. J Clin Endocrinol Metab. 1954; 14 (9): 1069-1073.
- [43] Ritter C, Göbel CH, Liebig T, Kaminsky E, Fink GR, Lehmann HC. *An epigenetic cause of seizures and brain calcification: pseudohypoparathyroidism*. The Lancet. 2015; 385 (9979): 1802.
- [44] SP, Narayanaswamy null, Mathias NJ, Konan VK. *Pseudohypoparathyroidism-A Rare Cause of Seizures in a Young Male*. J Assoc Physicians India. 2023; 71 (1): 1.
- [45] Salemi P, Skalamera JM, Olson, Dickson LE, Germain-Lee EL. *Ossifications in Albright Hereditary Osteodystrophy: Role of Genotype, Inheritance, Sex, Age, Hormonal Status, and BMI*. J Clin Endocrinol Metab. 2017; 103 (1): 158-168.
- [46] Scheffer IE, Berkovic S, Capovilla G, Connolly MB, French J, Guilhoto L, et al. *ILAE classification of the epilepsies: Position paper of the ILAE Commission for Classification and Terminology*. Epilepsy. 2017; 58 (4): 512-521.
- [47] Srivastava G, Apovian C. *Future Pharmacotherapy for Obesity: New Anti-obesity Drugs on the Horizon*. Curr Obes Rep. 2018; 7 (2): 147-161.
- [48] Sunder R, Singh M. *Pseudohypoparathyroidism: a series of three cases and an unusual presentation of ocular tetany*. Anaesthesia. 2006; 61 (4): 394-398.
- [49] Swami A, Kar G. *Intracranial hemorrhage revealing pseudohypoparathyroidism as a cause of fahr syndrome*. Case Rep Neurol Med. 2011; 2011: 407567.
- [50] Wang Y, Xu C, Xu Z, Ji C, Liang J, Wang Y, et al. *Depolarized GABAergic Signaling in Subicular Microcircuits Mediates Generalized Seizure in Temporal Lobe Epilepsy*. Neuron. 2017; 95 (1): 92-105. e5.
- [51] Weinstein L. S. *The Stimulatory G Protein α -Subunit Gene: Mutations and Imprinting Lead to Complex Phenotypes*. J Clin Endocrinol Metab. 2001; 86 (10): 4622-4626.
- [52] Yamada K, Tamura Y, Yamamoto M, Kumagai A. *Effect of calcium administration on renal responsiveness to parathyroid hormone in pseudohypoparathyroidism type I and II -- in comparison with normal, idiopathic and surgical hypoparathyroidism*. Endocrinol Jpn. 1979; 26 (2): 147-157.
- [53] Yamamoto Y, Noto Y, Saito M, Ichizen H, Kida H. *Spinal cord compression by heterotopic ossification associated with pseudohypoparathyroidism*. J Int Med Res. 1997; 25 (6): 364-368.
- [54] Yin XM, Lin JH, Cao L, Zhang TM, Zeng S, Zhang KL, et al. *Familial paroxysmal kinesigenic dyskinesia is associated with mutations in the KCNA1 gene*. Hum Mol Genet. 2018; 27 (4): 625-637.
- [55] *Pseudohypoparathyroidism: Diagnosis and Treatment | The Journal of Clinical Endocrinology & Metabolism | Oxford Academic* [online].
- [56] *GNAS GNAS complex locus [Homo sapiens (human)] - Gene - NCBI* [online]. [cited August 17, 2023]. Available at: <https://www.ncbi.nlm.nih.gov/gene/2778#gene-expression>.
- [57] *Pseudohypoparathyroidism Type Ia: Late Presentation with Intact Mental Development - Rutter - 1998 - Journal of Bone and Mineral Research - Wiley Online Library* [online].
- [58] *Mutation of the PDGFRB gene as a cause of idiopathic basal ganglia calcification | Neurology* [online].
- [59] *Cognitive and behavioral phenotype of children with pseudohypoparathyroidism type IA - Perez - 2018 - American Journal of Medical Genetics Part A - Wiley Online Library*.
- [60] *EBSCOhost | 70956799 | The nature of the calcified structures in the brain in hypoparathyroidism*.